



2024. Номер 9, С 164 – 177

Отримано: 04.03.2024 Прийнято: 22.04.2024 Опубліковано: 23.05.2024

DOI: 10.31890/vttp.2024.09.16

UDC 636.082.31.082.451:577.1-022.532:612.014.43:616.379-008.64

EFFECTS OF NANOBIMATERIAL-BASED ANTIOXIDANTS ON TESTIS HISTOMORPHOLOGY OF MALES UNDER HEAT STRESS OR DIABETES

S.V. Naumenko¹, O.S. Miroshnikova¹, V.I. Koshevoy¹, G.V. Vikulina¹,
O.L. Orobchenko¹, O.Ye. Zhigalova¹, V.K. Klochkov², S.L. Yefimova²

¹State Biotechnological University, Kharkiv, Ukraine

²Institute for Scintillation Materials of the NAS of Ukraine, Kharkiv, Ukraine

E-mail: frolka001@gmail.com

Annotation. Male infertility is an urgent problem of veterinary reproductive medicine. According to the latest scientific trends, oxidative stress is the main pathogenetic mechanism of its occurrence. It is known that such common pathological conditions as heat stress and diabetes can lead to disturbances in the functional activity and histoarchitectonics of male gonads. To correct the changes accompanying these conditions, many compounds with antioxidant properties, including nanostructured ones, have been proposed. Therefore, the goal of our research was to substantiate the effect of antioxidant preparations based on nanobiomaterials on the histostructure of the male gonads of domestic animals under the influence of heat stress or the influence of diabetes. Males of two species of animals were chosen for the study: rabbits of the Hyplus breed (n=12) and boars breed line big white × yorkshire (n=10). Animals were randomly divided into two groups: control and experimental. Diabetes was reproduced in rabbits using a commonly used alloxan model, controlling hyperglycaemia biochemically. Boars were kept at elevated environmental temperatures in the summer, showing infertility due to deterioration in the quality of ejaculates. For the correction of antioxidant protection, a research group of boars was given a combined administration of vitamin A and nanoparticles of gadolinium orthovanadate, and for this purpose α -lipoic acid and N-acetylcysteine were given to rabbits. When examining histological sections of the testes of control group animals, typical changes were revealed: most of the tubules were empty. In some animals, spermatogenesis was stopped at the stage of formation of spermatids, which prevented the formation of morphologically complete spermatozoa and, as a result, their complete absence in the lumen of the tubules. The epithelium of tubules was characterized by dystrophic changes. The diameter of the seminiferous tubules was much smaller. Also, the number and size of interstitial endocrinocytes and their nuclei were reduced; polymorphism, a decrease in the oxyphilic properties of the cytoplasm and vacuolation phenomena were observed. During antioxidant correction, restoration of the structure of the testes under heat stress was noted in boars: the diameter of convoluted seminiferous tubules increased by 31.3% ($p<0.05$), the presence of mature spermatozoa in the tubules, an increase in the number of interstitial endocrinocytes and their nuclei was noted. The introduction of α -lipoic acid and N-acetylcysteine contributed to the normalization of the morphology of the rabbit's gonads with alloxan-induced diabetes mellitus, a decrease in interstitial oedema and the presence of signs of preservation of spermatogenesis were observed, some convoluted tubules were restored, which in general led to an increase in their diameter by 37.3 % ($p<0.05$).

Key words: testes, antioxidant, vitamin A, α -lipoic acid, nanoparticles, interstitial endocrinocytes, morphology.

ВПЛИВ АНТИОКСИДАНТНИХ ПРЕПАРАТІВ НА ОСНОВІ НАНОБІОМАТЕРІАЛІВ НА ГІСТОМОРФОЛОГІЮ СТАТЕВИХ ЗАЛОЗ САМЦІВ ЗА ДІЇ ТЕПЛОВОГО СТРЕСУ АБО ЦУКРОВОГО ДІАБЕТУ

С.В. Науменко¹, О.С. Мірошнікова¹, В.І. Кошевой¹, Г.В. Вікуліна¹,
О.Л. Орбаченко¹, О.Є. Жигалова¹, В.К. Клочков², С.Л. Єфімова²

¹Державний біотехнологічний університет, м. Харків, Україна

²Інститут сцинтиляційних матеріалів НАН України, м. Харків, Україна

E-mail: frolka001@gmail.com

Анотація. Неплідність самців є актуальною проблемою ветеринарної репродуктології, а відповідно останнім науковим дослідженням доведено, що провідним патогенетичним механізмом у її виникненні є оксидативний стрес. Відомо, що такі поширені патологічні стани, як тепловий стрес і цукровий діабет здатні призводити до порушень функціональної активності та гістоархітекtonіки статевих залоз самців. Для корекції змін, якими супроводжуються дані стани, запропоновано велику кількість сполук з антиоксидантними властивостями, в тому числі, і наноструктурованих. Отже, метою наших досліджень було обґрунтувати вплив антиоксидантних препаратів на основі нанобіоматеріалів на гістоструктурні параметри статевих залоз самців свійських тварин за дії теплового стресу або впливу цукрового діабету. Для цього було самців двох видів – кролів породи Хіплус (n=12) і кнурів породної лінії велика біла × йоркшир (n=10), що були випадковим чином розділені на дві групи – контрольну і дослідну. Кролям відтворювали цукровий діабет, використовуючи алоксанову модель, контролюючи гіперглікемію біохімічно. Кнурів утримували за підвищених температур навколишнього середовища в літній період, виявляючи неплідність за погіршенням якості еякулятів. Дослідній групі кнурів для корекції антиоксидантного захисту застосовували комбіноване введення вітаміну А і наночастинок гадолінію ортованадату, а кролям з цією метою задавали α -ліпоєву кислоту і N-ацетилцистеїн. При дослідженні гістопрепаратів сім'яників тварин контрольних груп були виявлені типові зміни – більшість каналців були спустошеними, у деяких із них процеси сперматогенезу були зупинені на стадії утворення сперматид, що унеможливило утворення морфологічно повноцінних спермій і, як наслідок, повну відсутність їх у просвіті цих каналців. Епітелій цих каналців характеризувався дистрофічними змінами. Діаметр таких сім'яних каналців був значно меншим. Також, зменшеними були кількість і розміри клітин Лейдіга та їх ядер – вони відрізнялися поліморфізмом, зниженими оксифільними властивостями цитоплазми і явищами вакуолізації. За антиоксидантної корекції у кнурів відзначали відновлення структури сім'яників за теплового стресу: діаметр звивистих сім'яних каналців збільшувався на 31,3 % ($p < 0,05$), в каналцях відмічали наявність зрілих спермій, збільшення кількості клітин Лейдіга та їх ядер порівняно з контрольною групою. Введення α -ліпоєвої кислоти та N-ацетилцистеїну сприяло нормалізації морфології статевих залоз кролів за алоксан-індукованого цукрового діабету, а саме зменшення набряку інтерстицію, наявність у більшості каналців ознак збереження сперматогенезу, при чому деякі каналці вже були відновленими, що в цілому привело до зростання їх діаметру на 37,3 % ($p < 0,05$).

Ключові слова: сім'яники, антиоксиданти, вітамін А, α -ліпоєва кислота, наночастинки, інтерстиціальні ендокриноцити, морфологія.

Introduction. Relevance of theme. Heat stress and diabetes are pathological conditions accompanied by the development of oxidative stress and are of leading importance in the occurrence of infertility in both animals and humans (Aitken & Baker, 2006; Agarwal et al., 2017; Peña et al., 2021). Such stressful conditions can cause changes in the dynamics of testicular

microvascular blood flow, endocrine signalling, germ cell apoptosis, etc (Usala et al., 2021; Xia et al., 2022; Roths et al., 2023). Oxidative stress arising from sustained exposure to high environmental temperatures and prolonged hyperglycaemia appears to be a common feature in most processes underlying male infertility (Koppers et al., 2011; Koshevoy & Naumenko, 2022). This certainly indicates that there may be benefit from the development of antioxidant therapy for relevant cases of spermatogenesis and ejaculate quality disorders due to heat stress and diabetes (Turner & Lysiak, 2008; Koshevoy et al., 2022; Zhang et al., 2022).

Under oxidative stress, which develops intensively during heat stress and diabetes, an increased level of active forms of oxygen (AFO, ROS - reactive oxygen species) attacks cellular macromolecules, which leads to DNA damage, lipid and protein peroxidation, mitochondrial dysfunction, and disruption of structural sperm integrity (Paoli et al., 2011; Li et al., 2014a; Dehdari Ebrahimi et al., 2023). The damage is aggravated by a change in the apoptotic index, vacuolization of cells and a decrease in the ability to proliferate, with a subsequent decrease in the viability and number of sperm (de Lamirande & Gagnon, 1992; Othman et al., 2016; Singh & Singh, 2019). It is important to note that among different cell types, sperm are highly vulnerable to oxidation due to the high amount of unsaturated fatty acids in the membrane, the lack of proper DNA repair mechanisms, and the absence of cytoplasmic antioxidant enzymes, which leads to concomitant negative consequences for sperm quality (Venkatesh et al., 2011; Agarwal et al., 2017; Koshevoy et al., 2021b).

Morphological changes in the testes as a consequence of the hyperglycaemic effect of diabetes mellitus (DM) have been documented (Shrilatha & Muralidhara 2007; Corrêa et al., 2019; Sozen et al., 2022). The diabetes affects spermatogenesis changing the morphology of male gonads (Agbaje et al., 2007; Gumieniczek & Wilk, 2009). Reduction of seminiferous and epididymal tubules, changes in sperm parameters, decrease in the index of sustentacular cells, as well as damage to the morphology of the epithelium with depletion and apoptosis of germ cells are associated with impaired spermatogenesis under the influence of oxidative stress (Maremanda et al., 2016). Damage to the vimentin filaments of sustentacular cells causes germ cells dissociation, leading to apoptosis, which may lead to changes in sperm under the effect of DM (Alves et al., 2013; Xu et al., 2014; Zhang et al., 2024b). Thus, an urgent problem is the development of antioxidant drugs for the correction of histopathological changes and sperm quality in males under the effects of heat stress or diabetes.

Analysis of recent research and publications. Supplements with antioxidants are of fundamental importance in preventing damage due to oxidative stress, which causes a decrease in reproductive capacity and structural and functional changes in the gonads (Mohasseb et al., 2011; Aguirre-Arias et al., 2017; Corrêa et al., 2019). Modern research substantiates the possibility of using many compounds as means of antioxidant therapy, among them α -lipoic acid, melatonin, silymarin, Manganese, Selenium, extracts of *Chlorella vulgaris* and *Nigella Sativa*, pomegranate juice, the drug Proksid Plus and a complex drug based on Chinese herbs. Although they exhibit pronounced redox activity, the mechanisms of their influence in different forms and causes of infertility (heat stress, diabetes, toxic factors, etc.) are not the same, but have common features (El-Sayed et al., 2021; Lee et al., 2021; Bejaoui et al., 2023).

The antioxidant effect of α -lipoic acid (α LC) during the development of diabetes occurs by lowering the level of glycemia (Goraça et al., 2011). A decrease in the content of OS markers was noted with an increase in the activity of superoxide dismutase and glutathione peroxidase with the introduction of α LC associated with vitamin C and vitamin E, which led to an improvement in the morphology of the testes. α LC is known for its potential to regenerate other antioxidants, such as vitamin C and vitamin E, and has been proposed in therapeutic regimens to reduce oxidative stress in DM (González-Pérez et al., 2008; Abdali et al., 2015).

The activity of antioxidant enzymes in the homogenate of testes under the influence of melatonin was significantly higher than in the methotrexate group. In contrast, levels of oxidative stress biomarkers and inflammatory factors were markedly reduced after melatonin treatment. In addition, in the melatonin group, pathological lesions and apoptosis of testicular cells were

alleviated. Thus, the efficacy of melatonin administration against methotrexate-induced gonadal damage in rats has been shown (Wang et al., 2018).

On the other hand, experimental studies have shown that silymarin can compensate for the adverse effects of cadmium chloride on gonadal histopathology, testosterone levels, oxidative stress indicators, and antioxidant defence enzymes in mice (Faraji et al., 2019). Similar changes occur under the influence of formaldehyde; the mass of gonads, the number of sperm, their mobility, viability, and morphology in mice decreases. In addition, it was found that seminiferous tubules were atrophied, and sustentacular cells were damaged. It was possible to improve these changes with the introduction of Manganese supplements into the diet, which can protect sperm in the epididymis and the structure of testes damaged by formaldehyde (Tajaddini et al., 2014).

Another mechanism for improving reproductive performance is the combined effect of antioxidants on biochemical parameters and the spermatogonial stem cell (SSC) population. Thus, it was shown that the concentration of selenium in the blood and spermatozoa of animals progressively increased with an increase in its level in the diet. The highest activity of glutathione peroxidase and the lowest content of malondialdehyde were obtained with the addition of 0.5 mg/kg. At the same time, the analysis showed that the mRNA expression of SSC markers was significantly lower in the control group and the 1.0 mg/kg group compared to that with the addition of 0.5 mg/kg. A similar trend was observed in the population of SCC analysed by the method of immunofluorescence analysis. These data suggest that dietary Selenium can affect the SSC population in the gonads of roosters during spermatogenesis and improve oxidative status (Shi et al., 2014).

The toxic effect of carbon tetrachloride leads to a decrease in antioxidant enzymes and the number and viability, normal morphology, and motility of sperm, and also significantly increases markers of oxidative stress in rats. Addition of *Chlorella vulgaris* extract to the diets of rats exposed to carbon tetrachloride causes a significant decrease in markers of oxidative stress and improves antioxidant status in the gonads. There is also an increase in the number of spermatozoa with rectilinear-progressive movement, normal morphology, and viability. Overall, it has been shown that *Chlorella vulgaris* extract can play a crucial role in attenuating carbon tetrachloride-induced oxidative stress by protecting sperm membrane and DNA from oxidative damage (Ranjbar et al., 2022).

The influence of monosodium glutamate causes changes in the histomorphometry of testes, in particular pronounced atrophy of seminiferous tubules with degeneration of their lining cells, damage to interstitial endocrinocytes and a decrease in the number of germ cells. Whereas dietary administration of *Nigella Sativa* extract mitigates MSG-induced testicular damage due to its antioxidant and cytoprotective activity (Abd-Elkareem et al., 2021).

For the administration of lead, it was proven that the highest rate of lead loading was in the kidneys and testicles, in which morphological damage was detected. Pomegranate juice helped reduce the level of lead in the body of rats, increase the amount of Zinc in gonadal tissues, and limited oxidative stress by reducing lipid peroxidation, improved the activity of antioxidant enzymes, and the level of glutathione (Aksu et al., 2017).

Several dosage forms of drugs for the treatment of infertility and improvement of sexual function have been developed: a complex drug based on Chinese herbs and Proxid Plus (El-Kholy et al., 2021). It was found that the Proxid Plus alleviates histological changes in rats, increases the activity of spermatogenesis, the diameter of the seminiferous tubules, the number of active interstitial endocrinocytes, and reduces the expression of inducible nitric oxide synthase (Sangodele et al., 2021). A patented complex preparation based on Chinese herbs preserves testicular morphology and spermatogenesis (Li et al., 2021). Therefore, a wide range of antioxidant agents can have a positive effect on the damaged morphology of the testicles and contribute to the restoration of spermatogenesis and the protection of sperm from oxidative stress.

The purpose of work is to experimentally substantiate the effect of antioxidant preparations based on nanobiomaterials on the histostructure of the male gonads of domestic animals under the influence of heat stress or diabetes.

Objectives of study:

1. To determine the histopathological changes in the boar's testes under the effects of heat stress and after correction with a combination of vitamin A and nanoparticles of gadolinium orthovanadate.

2. To conduct a study of the histomorphology of the rabbit's gonads with alloxan-induced diabetes and the administration of antioxidant agents: N-acetylcysteine and α -lipoic acid.

Material and methods. The research was carried out in the laboratories of the Faculty of Veterinary Medicine of the State Biotechnological University. The males of two animal species were used: rabbits of the Hyplus breed (n=12) and boars (n=10). The animals were randomly divided into two groups: control and experimental. Males of the control groups were kept on a standard diet, had free access to water and food. The experiment was carried out in two directions: the study of the histomorphology of the rabbit's gonads under alloxan-induced diabetes and the histological assessment of the boar's testes under the effects of heat stress.

In organizing and conducting experiments, the authors of the article followed the provisions of the "European Convention on the Protection of Vertebrate Animals Used for Experimental and Scientific Purposes" (Strasbourg, 1986), the 1st National Congress on Bioethics (Kyiv, 2001) and the Law of Ukraine "On the Protection of Animals from ill-treatment" (2006).

The boar's testes were selected by castration at the end of the experiment. To simulate the heat stress of boars, the study was conducted from May to September with an average ambient temperature of 30-32 °C (Mayorga et al., 2018; Sui et al., 2022). The negative impact of a moderate increase in temperature was assessed by indicators of ejaculate quality as recommended (Fan et al., 2017). Correction of antioxidant protection in boars of the research group was carried out by the combined introduction of vitamin A and nanoparticles of gadolinium orthovanadate into the diet in recommended doses (Koshevoy et al., 2021a; Naumenko et al., 2021).

Diabetes mellitus was modulated in rabbits by four intraperitoneal injections of alloxan at a dose of 80 mg/kg body weight at weekly intervals after a 12-hour fasting diet (according to the method of Mir & Darzi, 2009). The development of diabetes was confirmed on the 7th day by determining the level of fasting glucose in blood taken from the cranial ear vein. Animals of the control group received an injection of distilled water according to a similar protocol. 7 weeks after the start of the experiment, the animals were given antioxidants – α -lipoic acid and N-acetylcysteine. At the end of the experiment, all animals were euthanized, and the organs were selected for histological examination.

After dissection and macroscopic examination, the testes were fixed in a 10% aqueous solution of neutral formalin. Histological sections were made according to the generally accepted technique with embedding in paraffin and subsequent staining with haematoxylin and eosin (Horalsky, 2015).

All data were processed statistically by Microsoft EXCEL software. The obtained data from the rabbits of all groups were analysed using one-way analysis of variance (ANOVA). The significant changes among indexes at probability were examined by Duncan's Multiple Range Test. The records in the tables were presented as mean \pm standard error means (SEM). The differences between groups were considered statistically significant at $P < 0.05$.

Results and discussion. The effect of nanobiomaterial-based drugs on the structure of the tissues of the male's gonads was evaluated in comparison with the control group. According to the histological structure, the testes of mature males are characterized by the presence in the spermatogenic epithelium of cells at different stages of spermatogenesis, from spermatogonia to spermatozoa, which are freely located in the lumen of convoluted seminiferous tubules. Among the cells of the spermatogenic epithelium, the overwhelming majority are spermatocytes of the II order and spermatids at various stages of maturation.

Sustentacular cells closely adhere to the basal membrane of tubules. The tubule wall has a three-layered structure. It is represented by a basal membrane, a layer of myoid cells and a fibrous sheath. Convoluted seminiferous tubules are surrounded by a network of small capillaries, and interstitial endocrinocytes of various sizes are in the parenchyma of testes.

During the examination of histological sections of the testes of the animals of the control groups, the following changes were found: most of the tubules were empty; the spermatogenesis was stopped at the stage of spermatids formation, which made it impossible to form morphologically complete sperms and, as a result, their complete absence in the lumen of these tubules; interstitial oedema was noted. The epithelium of tubules was characterized by dystrophic changes. The diameter of such seminiferous tubules was much smaller. Also, the number and size of interstitial endocrinocytes and their nuclei were reduced. They were distinguished by polymorphism, reduced oxyphilic properties of the cytoplasm and phenomena of vacuolization.

Dystrophic changes were determined in boars under the effects of heat stress on histological sections (Fig. 1), which led to a decrease in the diameter of the convoluted seminiferous tubules (Fig. 2) due to the reduction of myoid cells of its wall, most of the tubules had a wavy contour of the wall and detachment of the cells of the spermatogenic epithelium. At the same time, preservation of the cambial layer (spermatogonia) (2*) was established.

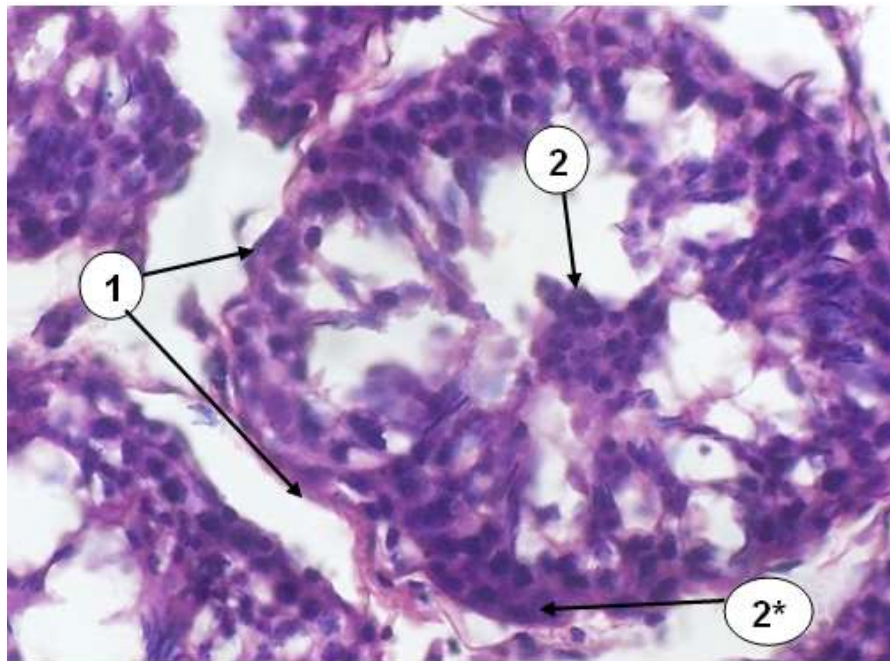


Fig. 1. Cross section of the convoluted tubule of boar's testis (control group), (hematoxylin-eosin staining, approx. 10×, ob. 40×): 1. Wavy contour and decrease in the diameter of the tubule due to the reduction of the myoid cells of its wall. 2. Defoliation of the cells of spermatogenic epithelium, but preservation of the cambial layer (spermatogonia) (2*).

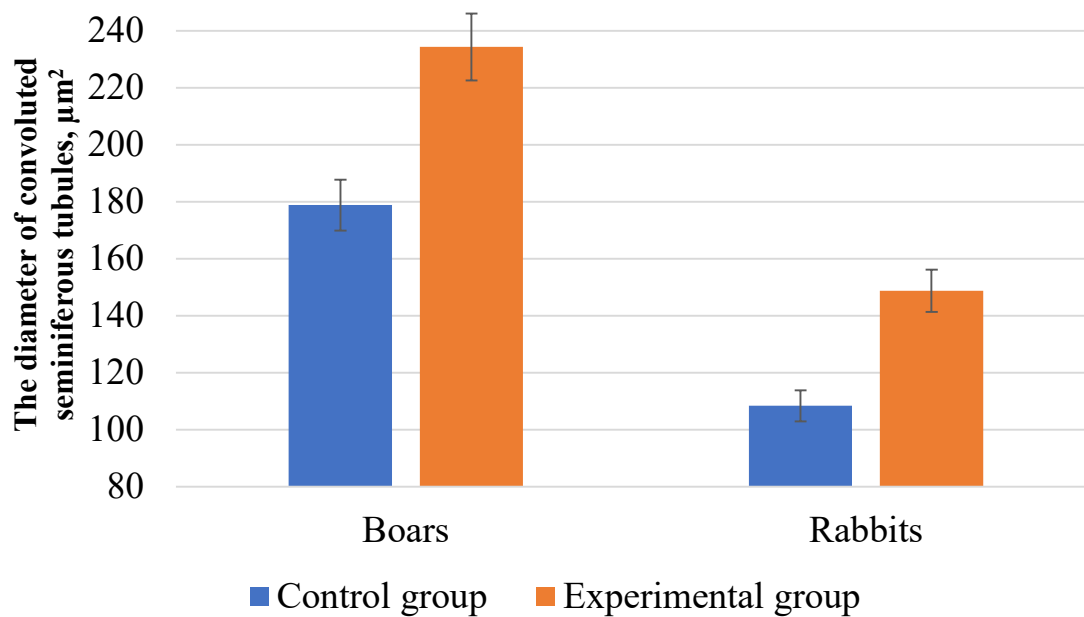


Fig. 2. Changes in the diameter of convoluted seminiferous tubules in male gonads after antioxidant correction.

Quantitative assessment of spermatogenesis corresponded to the microscopic picture of the histological sections of the testes of fertile animals and indicated a partial loss of tubules of spermatogenic function. Dystrophy of convoluted seminiferous tubules and destruction of spermatogenic cells at various stages of development, with filling of the lumen of the tubules with a granular mass with spermatogonia, spermatocytes, and spermatids, were found in various parts of the testis parenchyma. In separate sections of convoluted seminiferous tubules, deformed sperm of various stages of development, shadows of sperm, desquamated basement membrane and spermatogenic epithelium were found.

After therapy with the developed drug, the restoration of the structural organization of the male's testes was observed. Most of the tubules contained signs of preservation of spermatogenesis, and some tubules were almost restored. A decrease in interstitial oedema was noted. The presence of mature spermatozoa was noted in the tubules, which indicates the completion of the stages of spermatogenesis. The diameter of convoluted seminiferous tubules, the number and size of interstitial endocrinocytes and their nuclei reliable increased in comparison with indicators of animals of the control group.

The combined use of vitamin A with nanoparticles of gadolinium orthovanadate contributed to the restoration of the structure of the boar's testes under heat stress. A reliable increase in the diameter of convoluted seminiferous tubules by 31.3% ($p < 0.05$) was established. Under the drug influence, an increase in the number of interstitial endocrinocytes was detected. There was an increase the area of interstitial endocrinocytes and their nuclei, that increased the nuclear-cytoplasmic ratio. The histostructure of boar's testes under heat stress after the administration of corrective agents is shown in Fig. 3. The obtained data are consistent with the experimental model of infertility in mice against the background of heat stress (Li et al., 2014b) and similar experiments on breeding boars in vitro or in vivo conditions (Martín-Hidalgo et al., 2020; Deng et al., 2022; Liu et al., 2022; Zhang et al., 2024a).

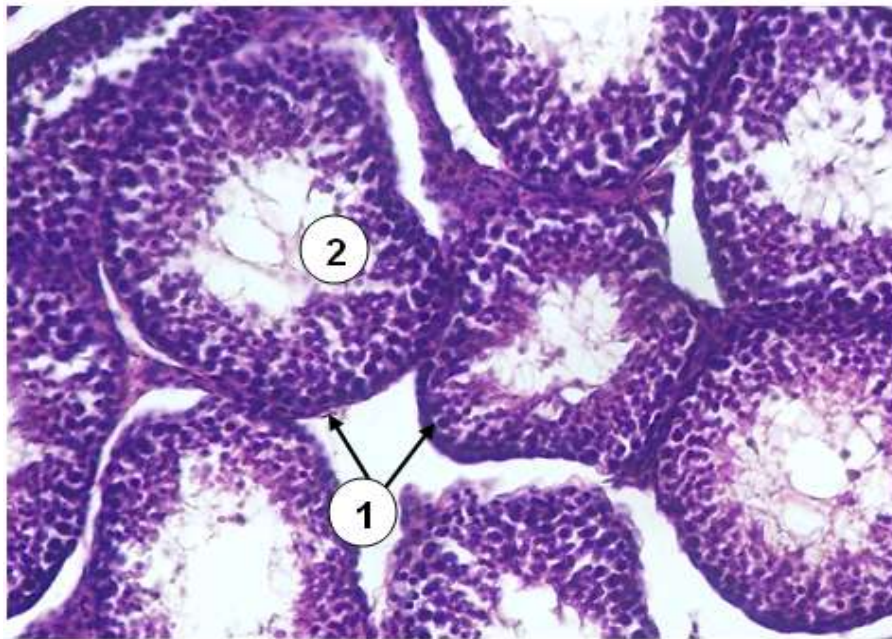


Fig. 3. **The histostructure of the boar testis after drug administration** (approx. $\times 10$, vol. $\times 20$, hematoxylin-eosin staining): 1. Wall of the convoluted tubule of testis. 2. Spermatogenic epithelium, restoration of all populations of germinal epithelium and its structural and functional contacts with sustentocytes (Sertoli cells).

It should be noted that the structure of the rabbit's testes with DM corresponded to the typical changes identified in boars: a decrease in the diameter of convoluted seminiferous tubules, the number of interstitial endocrinocytes and the development of dystrophic processes (Fig. 4). On the contrary, under the influence of α -lipoic acid and N-acetylcysteine, the structure of the gonads was restored; a reliable increase in the diameter of convoluted seminiferous tubules by 37.3% ($p < 0.05$) was established.

Fig. 5 shows the recovery of the germinal epithelium of the rabbit's testes with diabetes after antioxidant correction.

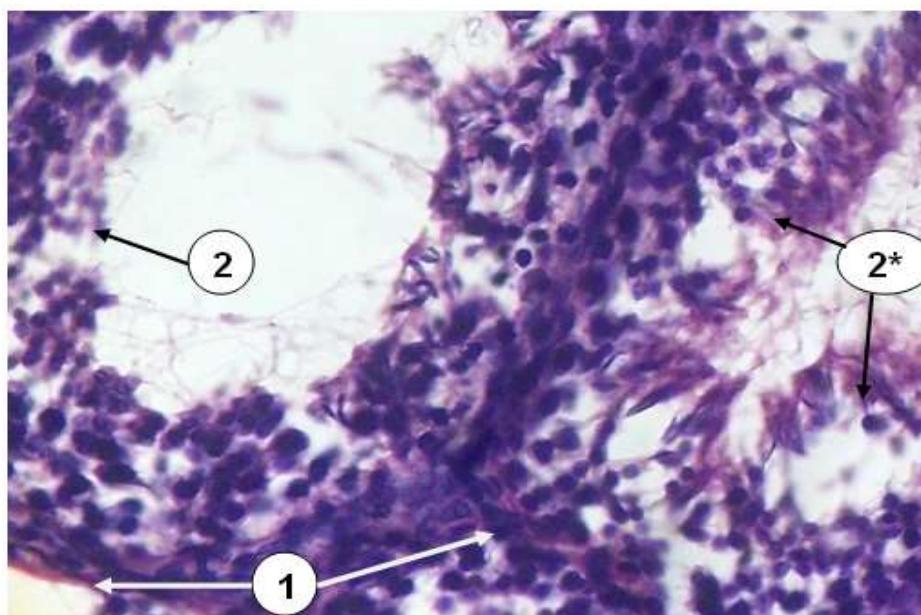


Fig. 4. **Cross section of the convoluted tubule of the rabbit' testis (control group)** (hematoxylin-eosin staining, approx. $10\times$, ob. $40\times$): 1. Wall of the convoluted tubule of testis; 2. Spermatogenic epithelium, absence of mature sperm on the luminal side of the tubule and detachment of spermatids and spermatocytes into the lumen of tubule (2*).

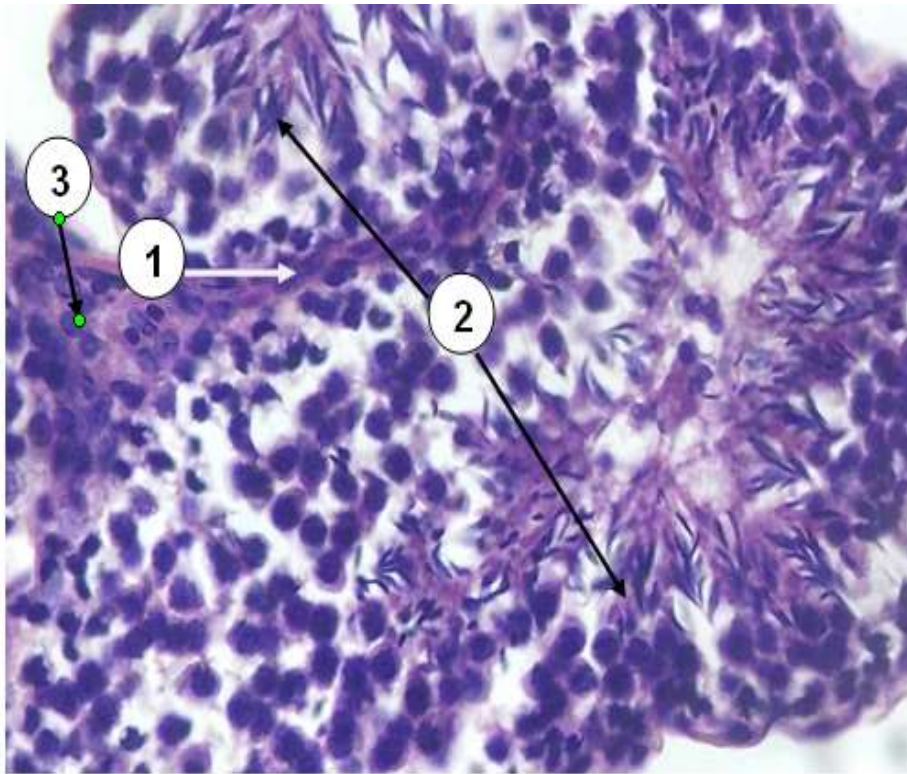


Fig. 5. **Cross section of the convoluted tubule of rabbit's testis (experimental group)** (hematoxylin-eosin staining, approx. 10×, ob. 40×): 1. Wall of the convoluted tubule of testis; 2. Spermatogenic epithelium, restoration of all populations of germinal epithelium and its structural and functional contacts with sustentocytes (Sertoli cells); 3. Interstitial endocrinocytes (Leydig cells).

Fig. 5 shows the increase in the number of interstitial endocrinocytes of the testes of rabbits of the experimental group. At the same time there was a simultaneous increase the area of interstitial endocrinocytes and their nuclei, that contributed to an increase in the nuclear-cytoplasmic ratio. The obtained results are consistent with the data of other authors, gonad disorder due to DM was characterized by changes in the morphology of the seminiferous epithelium, an increase in the amount of apoptosis in germ cells and interruption of spermatogenesis (Soudamani et al., 2005; Caiaffo et al., 2017; Ismail et al., 2023). Antioxidant correction reduced degeneration and disruption of seminiferous tubule structure and attenuated gonadal damage (Roy et al., 2015; El-Shobokshy et al., 2023). Taking into account the obtained changes, we consider it necessary to further clarify the effectiveness of antioxidant agents of organic nature and nanotechnological origin on the sexual function of males (Machado et al., 2021; El-Ratel et al., 2023; Naumenko et al., 2023).

Conclusions.

The conducted studies determined the presence of typical changes in the histomorphology of male testes under pathological conditions accompanied by the development of oxidative stress and experimentally substantiated the effectiveness of antioxidant correction means:

1. Under the effects of heat stress in the boar's testes or in the rabbit's gonads with alloxan-induced diabetes, typical morphological signs of disorders of the germinal-endocrine function were established: dystrophic changes in the interstitium, a decrease in the diameter of convoluted seminiferous tubules due to the reduction of myoid cells in their wall and detachment of cells of the spermatogenic epithelium.

2. With the combined use of vitamin A and nanoparticles of gadolinium orthovanadate, the restoration of the testes structure of boars under heat stress was noted: the diameter of the convoluted seminiferous tubules increased by 31.3% ($p < 0.05$), the presence of mature

spermatozoa in the tubules was noted, an increase the number of interstitial endocryocytes and their nuclei compared to the control group.

3. The introduction of α -lipoic acid and N-acetylcysteine contributed to the normalization of the morphology of the rabbit's gonads in alloxan-induced diabetes, namely, the reduction of interstitial oedema, signs of preservation of spermatogenesis in most tubules (some tubules were restored), increase of the tubules' diameter by 37.3% ($p < 0.05$).

Prospects for further research. The authors of the article consider the following areas of work as priorities, considering the obtained results – a complex biochemical justification of the remodelling of the structure of the testicles under pathological conditions using preparations based on nanobiomaterials and immunohistochemical analysis of the changes they cause.

References

1. Abdali, D., Samson, S. E., & Grover, A. K. (2015). How effective are antioxidant supplements in obesity and diabetes? *Medical Principles and Practice*, 24(3), 201–215. <https://doi.org/10.1159/000375305>
2. Abd-Elkareem, M., Abd El-Rahman, M. A. M., Khalil, N. S. A., & Amer, A. S. (2021). Antioxidant and cytoprotective effects of *Nigella sativa* L. seeds on the testis of monosodium glutamate challenged rats. *Scientific Reports*, 11(1), 13519. <https://doi.org/10.1038/s41598-021-92977-4>
3. Agarwal, A., Roychoudhury, S., Sharma, R., Gupta, S., Majzoub, A., & Sabanegh, E. (2017). Diagnostic application of oxidation-reduction potential assay for measurement of oxidative stress: clinical utility in male factor infertility. *Reproductive Biomedicine Online*, 34(1), 48–57. <https://doi.org/10.1016/j.rbmo.2016.10.008>
4. Agbaje, I. M., Rogers, D. A., McVicar, C. M., McClure, N., Atkinson, A. B., Mallidis, C., & Lewis, S. E. (2007). Insulin dependant diabetes mellitus: implications for male reproductive function. *Human Reproduction (Oxford, England)*, 22(7), 1871–1877. <https://doi.org/10.1093/humrep/dem077>
5. Aguirre-Arias, M. V., Velarde, V., & Moreno, R. D. (2017). Effects of ascorbic acid on spermatogenesis and sperm parameters in diabetic rats. *Cell and Tissue Research*, 370(2), 305–317. <https://doi.org/10.1007/s00441-017-2660-6>
6. Aitken, R. J., & Baker, M. A. (2006). Oxidative stress, sperm survival and fertility control. *Molecular and Cellular Endocrinology*, 250(1-2), 66–69. <https://doi.org/10.1016/j.mce.2005.12.026>
7. Aksu, D. S., Sağlam, Y. S., Yildirim, S., & Aksu, T. (2017). Effect of pomegranate (*Punica granatum* L.) juice on kidney, liver, heart and testis histopathological changes, and the tissues lipid peroxidation and antioxidant status in lead acetate-treated rats. *Cellular and Molecular Biology*, 63(10), 33–42. <https://doi.org/10.14715/cmb/2017.63.10.5>
8. Alves, M. G., Martins, A. D., Cavaco, J. E., Socorro, S., & Oliveira, P. F. (2013). Diabetes, insulin-mediated glucose metabolism and Sertoli/blood-testis barrier function. *Tissue Barriers*, 1(2), e23992. <https://doi.org/10.4161/tisb.23992>
9. Bejaoui, B., Sdiri, C., Ben Souf, I., Belhadj Slimen, I., Ben Larbi, M., Koumba, S., Martin, P., & M'Hamdi, N. (2023). Physicochemical Properties, Antioxidant Markers, and Meat Quality as Affected by Heat Stress: A Review. *Molecules (Basel, Switzerland)*, 28(8), 3332. <https://doi.org/10.3390/molecules28083332>
10. Caiaffo, V., Ribeiro de Oliveira, B. D., de Sa, F. B., Neto, J. E., & da Silva Junior, V. A. (2017). Marine Food Protection in Testicular Damages Caused by Diabetes Mellitus. *Current Diabetes Reviews*, 13(6), 566–572. <https://doi.org/10.2174/1573399812666160618123229>
11. Corrêa, L. B. N. S., da Costa, C. A. S., Ribas, J. A. S., Boaventura, G. T., & Chagas, M. A. (2019). Antioxidant action of alpha lipoic acid on the testis and epididymis of diabetic rats:

morphological, sperm and immunohistochemical evaluation. *International Brazilian Journal of Urology*, 45(4), 815–824. <https://doi.org/10.1590/S1677-5538.IBJU.2018.0774>

12. de Lamirande, E., & Gagnon, C. (1992). Reactive oxygen species and human spermatozoa. I. Effects on the motility of intact spermatozoa and on sperm axonemes. *Journal of Andrology*, 13(5), 368–378.

13. Dehdari Ebrahimi, N., Parsa, S., Nozari, F., Shahlaee, M. A., Maktabi, A., Sayadi, M., Sadeghi, A., & Azarpira, N. (2023). Protective effects of melatonin against the toxic effects of environmental pollutants and heavy metals on testicular tissue: A systematic review and meta-analysis of animal studies. *Frontiers in Endocrinology*, 14, 1119553. <https://doi.org/10.3389/fendo.2023.1119553>

14. Deng, C. C., Zhang, J. P., Huo, Y. N., Xue, H. Y., Wang, W., Zhang, J. J., & Wang, X. Z. (2022). Melatonin alleviates the heat stress-induced impairment of Sertoli cells by reprogramming glucose metabolism. *Journal of Pineal Research*, 73(3), e12819. <https://doi.org/10.1111/jpi.12819>

15. El-Kholy, K. H., Wafa, W. M., El-Nagar, H. A., Aboelmagd, A. M., & El-Ratel, I. T. (2021). Physiological response, testicular function, and health indices of rabbit males fed diets containing phytochemicals extract under heat stress conditions. *Journal of Advanced Veterinary and Animal Research*, 8(2), 256–265. <https://doi.org/10.5455/javar.2021.h510>

16. El-Ratel, I. T., Elbasuny, M. E., El-Nagar, H. A., Abdel-Khalek, A. E., El-Raghi, A. A., El Basuini, M. F., El-Kholy, K. H., & Fouda, S. F. (2023). The synergistic impact of Spirulina and selenium nanoparticles mitigates the adverse effects of heat stress on the physiology of rabbit's bucks. *PLoS One*, 18(7), e0287644. <https://doi.org/10.1371/journal.pone.0287644>

17. El-Sayed, A. I., Ahmed-Farid, O., Radwan, A. A., Halawa, E. H., & Elokil, A. A. (2021). The capability of coenzyme Q10 to enhance heat tolerance in male rabbits: evidence from improved semen quality factor (SQF), testicular oxidative defense, and expression of testicular melatonin receptor MT1. *Domestic Animal Endocrinology*, 74, 106403. <https://doi.org/10.1016/j.domaniend.2019.106403>

18. El-Shobokshy, S. A., Abo-Samaha, M. I., Sahwan, F. M., El-Rheem, S. M. A., Emam, M., & Khafaga, A. F. (2023). Implication of apoptosis and oxidative stress in mitigation of ivermectin long-term hazards by zinc nanoparticles in male rabbits. *Environmental Science and Pollution Research International*, 30(10), 26982–26997. <https://doi.org/10.1007/s11356-022-24095-1>

19. Fan, X., Xi, H., Zhang, Z., Liang, Y., Li, Q., & He, J. (2017). Germ cell apoptosis and expression of Bcl-2 and Bax in porcine testis under normal and heat stress conditions. *Acta Histochemica*, 119(3), 198–204. <https://doi.org/10.1016/j.acthis.2016.09.003>

20. Faraji, T., Momeni, H. R., & Malmir, M. (2019). Protective effects of silymarin on testis histopathology, oxidative stress indicators, antioxidant defence enzymes and serum testosterone in cadmium-treated mice. *Andrologia*, 51(5), e13242. <https://doi.org/10.1111/and.13242>

21. González-Pérez, O., Moy-López, N. A., & Guzmán-Muñiz, J. (2008). Alpha-tocopherol and alpha-lipoic acid. An antioxidant synergy with potential for preventive medicine. *Revista de Investigacion Clinica*, 60(1), 58–67.

22. Gorąca, A., Huk-Kolega, H., Piechota, A., Kleniewska, P., Ciejka, E., & Skibska, B. (2011). Lipoic acid – biological activity and therapeutic potential. *Pharmacological Reports*, 63(4), 849–858. [https://doi.org/10.1016/s1734-1140\(11\)70600-4](https://doi.org/10.1016/s1734-1140(11)70600-4)

23. Gumieniczek, A., & Wilk, M. (2009). Nitrosative stress and glutathione redox system in four different tissues of alloxan-induced hyperglycemic animals. *Toxicology mechanisms and methods*, 19(4), 302–307. <https://doi.org/10.1080/15376510902839762>

24. Horalsky L. P. (ed.). (2015). *Basics of histological technique and morphofunctional research methods in normal and pathological conditions*. Zhytomyr: Polissya. 286 p.

25. Ismail, H. Y., Shaker, N. A., Hussein, S., Tohamy, A., Fathi, M., Rizk, H., & Wally, Y. R. (2023). Cisplatin-induced azoospermia and testicular damage ameliorated by adipose-

derived mesenchymal stem cells. *Biological Research*, 56(1), 2. <https://doi.org/10.1186/s40659-022-00410-5>

26. Koppers, A. J., Mitchell, L. A., Wang, P., Lin, M., & Aitken, R. J. (2011). Phosphoinositide 3-kinase signalling pathway involvement in a truncated apoptotic cascade associated with motility loss and oxidative DNA damage in human spermatozoa. *The Biochemical Journal*, 436(3), 687–698. <https://doi.org/10.1042/BJ20110114>

27. Koshevoy, V. I., & Naumenko, S. V. (2022). Dynamics of peroxidation processes in male rabbits under experimental LPS-induced oxidative stress. *Veterynarna biotekhnolohiia – Veterinary biotechnology*, 41, 100–107. https://doi.org/10.31073/vet_biotech41-10

28. Koshevoy, V. I., Naumenko, S. V., Klochkov, V. K., & Yefimova, S. L. (2021a). The use of gadolinium orthovanadate nanoparticles for the correction of reproductive ability in boars under oxidative stress. *Ukrainian Journal of Veterinary Sciences*, 12(2), 74–82. <https://doi.org/10.31548/ujvs.2021.02.008>

29. Koshevoy, V., Naumenko, S., Skliarov, P., Fedorenko, S., & Kostyshyn, L. (2021b). Male infertility: Pathogenetic significance of oxidative stress and antioxidant defence (review). *Scientific Horizons*, 24(6), 107–116. [https://www.doi.org/10.48077/scihor.24\(6\).2021.107-116](https://www.doi.org/10.48077/scihor.24(6).2021.107-116)

30. Koshevoy, V., Naumenko, S., Skliarov, P., Syniahovska, K., Vikulina, G., Klochkov, V., & Yefimova, S. (2022). Effect of gadolinium orthovanadate nanoparticles on male rabbits' reproductive performance under oxidative stress. *World's Veterinary Journal*, 12(3), 296–303. <https://www.doi.org/10.54203/scil.2022.wvj37>

31. Lee, S., Kang, H. G., Jeong, P. S., Kim, M. J., Park, S. H., Song, B. S., Sim, B. W., & Kim, S. U. (2021). Heat stress impairs oocyte maturation through ceramide-mediated apoptosis in pigs. *The Science of the Total Environment*, 755(1), 144144. <https://doi.org/10.1016/j.scitotenv.2020.144144>

32. Li, L., Chen, B., An, T., Zhang, H., Xia, B., Li, R., Zhu, R., Tian, Y., Wang, L., Zhao, D., Mo, F., Li, Y., Yang, G., Orekhov, A. N., Prentki, M., Zhang, D., Jiang, G., & Zhu, X. (2021). BaZiBuShen alleviates altered testicular morphology and spermatogenesis and modulates Sirt6/P53 and Sirt6/NF-κB pathways in aging mice induced by D-galactose and NaNO₂. *Journal of Ethnopharmacology*, 271, 113810. <https://doi.org/10.1016/j.jep.2021.113810>

33. Li, X., Fang, E. F., Scheibye-Knudsen, M., Cui, H., Qiu, L., Li, J., He, Y., Huang, J., Bohr, V. A., Ng, T. B., & Guo, H. (2014a). Di-(2-ethylhexyl) phthalate inhibits DNA replication leading to hyperPARylation, SIRT1 attenuation, and mitochondrial dysfunction in the testis. *Scientific Reports*, 4, 6434. <https://doi.org/10.1038/srep06434>

34. Li, Y., Cao, Y., Wang, F., Pu, S., Zhang, Y., & Li, C. (2014b). Tert-butylhydroquinone attenuates scrotal heat-induced damage by regulating Nrf2-antioxidant system in the mouse testis. *General and Comparative Endocrinology*, 208, 12–20. <https://doi.org/10.1016/j.ygcen.2014.09.007>

35. Liu, F., Zhao, W., Le, H. H., Cottrell, J. J., Green, M. P., Leury, B. J., Dunshea, F. R., & Bell, A. W. (2022). Review: What have we learned about the effects of heat stress on the pig industry? *Animal*, 1(2), 100349. <https://doi.org/10.1016/j.animal.2021.100349>

36. Machado, N. A. F., Martin, J. E., Barbosa-Filho, J. A. D., Dias, C. T. S., Pinheiro, D. G., de Oliveira, K. P. L., & Souza-Junior, J. B. F. (2021). Identification of trailer heat zones and associated heat stress in weaner pigs transported by road in tropical climates. *Journal of Thermal Biology*, 97, 102882. <https://doi.org/10.1016/j.jtherbio.2021.102882>

37. Maremanda, K. P., Khan, S., & Jena, G. B. (2016). Role of zinc supplementation in testicular and epididymal damages in diabetic rat: involvement of Nrf2, SOD1, and GPX5. *Biological Trace Element Research*, 173(2), 452–464. <https://doi.org/10.1007/s12011-016-0674-7>

38. Martín-Hidalgo, D., Macías-García, B., García-Marín, L. J., Bragado, M. J., & González-Fernández, L. (2020). Boar spermatozoa proteomic profile varies in sperm collected during the summer and winter. *Animal Reproduction Science*, 219, 106513. <https://doi.org/10.1016/j.anireprosci.2020.106513>
39. Mayorga, E. J., Renaudeau, D., Ramirez, B. C., Ross, J. W., & Baumgard, L. H. (2018). Heat stress adaptations in pigs. *Animal Frontiers*, 9(1), 54–61. <https://doi.org/10.1093/af/vfy035>
40. Mir, S. H., & Darzi, M. M. (2009). Histopathological abnormalities of prolonged alloxan-induced diabetes mellitus in rabbits. *International Journal of Experimental Pathology*, 90(1), 66–73. <https://doi.org/10.1111/j.1365-2613.2008.00615.x>
41. Mohasseb, M., Ebied, S., Yehia, M. A., & Hussein, N. (2011). Testicular oxidative damage and role of combined antioxidant supplementation in experimental diabetic rats. *Journal of Physiology and Biochemistry*, 67(2), 185–194. <https://doi.org/10.1007/s13105-010-0062-2>
42. Naumenko, S. V., Koshevoi, V. I., Skliarov, P.M., Klochkov, V. K., & Yefimova, S. L. (2021). Effectiveness of using the complex drug “Karafand+OV,Zn” to increase the reproductive capacity of males of domestic animals. *Journal for Veterinary medicine, Biotechnology and Biosafety*, 7(4), 3–7. <https://doi.org/10.36016/JVMBBS-2021-7-4-1>
43. Naumenko, S., Koshevoy, V., Matsenko, O., Miroshnikova, O., Zhukova, I., & Bespalova, I. (2023). Antioxidant properties and toxic risks of using metal nanoparticles on health and productivity in poultry. *Journal of World's Poultry Research*, 13(3), 292–306. <https://www.doi.org/10.36380/jwpr.2023.32>
44. Othman, A. I., Edrees, G. M., El-Missiry, M. A., Ali, D. A., Aboel-Nour, M., & Dabdoub, B. R. (2016). Melatonin controlled apoptosis and protected the testes and sperm quality against bisphenol A-induced oxidative toxicity. *Toxicology and Industrial Health*, 32(9), 1537–1549. <https://doi.org/10.1177/0748233714561286>
45. Paoli, D., Gallo, M., Rizzo, F., Baldi, E., Francavilla, S., Lenzi, A., Lombardo, F., & Gandini, L. (2011). Mitochondrial membrane potential profile and its correlation with increasing sperm motility. *Fertility and Sterility*, 95(7), 2315–2319. <https://doi.org/10.1016/j.fertnstert.2011.03.059>
46. Peña, S. T., Jr, Stone, F., Gummow, B., Parker, A. J., & Paris, D. B. B. P. (2021). Susceptibility of boar spermatozoa to heat stress using in vivo and in vitro experimental models. *Tropical Animal Health and Production*, 53(1), 97. <https://doi.org/10.1007/s11250-020-02516-y>
47. Ranjbar, A., Satari, M., Mohseni, R., Tavilani, A., & Ghasemi, H. (2022). Chlorella vulgaris ameliorates testicular toxicity induced by carbon tetrachloride in male rats via modulating oxidative stress. *Andrologia*, 54(9), e14495. <https://doi.org/10.1111/and.14495>
48. Roths, M., Freestone, A. D., Rudolph, T. E., Michael, A., Baumgard, L. H., & Selsby, J. T. (2023). Environment-induced heat stress causes structural and biochemical changes in the heart. *Journal of Thermal Biology*, 113, 103492. <https://doi.org/10.1016/j.jtherbio.2023.103492>
49. Roy, V. K., Chenkual, L., & Gurusubramanian, G. (2015). Protection of testis through antioxidant action of Mallotus roxburghianus in alloxan-induced diabetic rat model. *Journal of Ethnopharmacology*, 176, 268–280. <https://doi.org/10.1016/j.jep.2015.11.006>
50. Sangodele, J. O., Inuwa, Z., Lawal, B., Adebayo-Gege, G., Okoli, B. J., & Mtunzi, F. (2021). Proxead plus salvage rat testis from ischemia- reperused injury by enhancing antioxidant's activities and inhibition of iNOS expression. *Biomedicine & Pharmacotherapy*, 133, 111086. <https://doi.org/10.1016/j.biopha.2020.111086>
51. Shi, L., Zhao, H., Ren, Y., Yao, X., Song, R., & Yue, W. (2014). Effects of different levels of dietary selenium on the proliferation of spermatogonial stem cells and antioxidant status in testis of roosters. *Animal Reproduction Science*, 149(3-4), 266–272. <https://doi.org/10.1016/j.anireprosci.2014.07.011>
52. Shrilatha, B., & Muralidhara (2007). Occurrence of oxidative impairments, response of antioxidant defences and associated biochemical perturbations in male reproductive

- milieu in the Streptozotocin-diabetic rat. *International Journal of Andrology*, 30(6), 508–518. <https://doi.org/10.1111/j.1365-2605.2007.00748.x>
53. Singh, S., & Singh, S. K. (2019). Chronic exposure to perfluorononanoic acid impairs spermatogenesis, steroidogenesis and fertility in male mice. *Journal of Applied Toxicology*, 39(3), 420–431. <https://doi.org/10.1002/jat.3733>
54. Soudamani, S., Malini, T., & Balasubramanian, K. (2005). Effects of streptozotocin-diabetes and insulin replacement on the epididymis of prepubertal rats: histological and histomorphometric studies. *Endocrine Research*, 31(2), 81–98. <https://doi.org/10.1080/07435800500229193>
55. Sozen, E., Demirel-Yalciner, T., Koroglu, M. K., Elmas, M. A., Ercan, F., & Ozer, N. K. (2022). High cholesterol diet activates ER stress mediated apoptosis in testes tissue: Role of α -tocopherol. *IUBMB Life*, 74(1), 85–92. <https://doi.org/10.1002/iub.2535>
56. Sui, H., Wang, S., Liu, G., Meng, F., Cao, Z., & Zhang, Y. (2022). Effects of Heat Stress on Motion Characteristics and Metabolomic Profiles of Boar Spermatozoa. *Genes*, 13(9), 1647. <https://doi.org/10.3390/genes13091647>
57. Tajaddini, S., Ebrahimi, S., Behnam, B., Bakhtiyari, M., Joghataei, M. T., Abbasi, M., Amini, M., Amanpour, S., & Koruji, M. (2014). Antioxidant effect of manganese on the testis structure and sperm parameters of formalin-treated mice. *Andrologia*, 46(3), 246–253. <https://doi.org/10.1111/and.12069>
58. Turner, T. T., & Lysiak, J. J. (2008). Oxidative stress: a common factor in testicular dysfunction. *Journal of Andrology*, 29(5), 488–498. <https://doi.org/10.2164/jandrol.108.005132>
59. Usala, M., Macciotta, N. P. P., Bergamaschi, M., Maltecca, C., Fix, J., Schwab, C., Shull, C., & Tiezzi, F. (2021). Genetic Parameters for Tolerance to Heat Stress in Crossbred Swine Carcass Traits. *Frontiers in Genetics*, 11, 612815. <https://doi.org/10.3389/fgene.2020.612815>
60. Venkatesh, S., Shamsi, M. B., Deka, D., Saxena, V., Kumar, R., & Dada, R. (2011). Clinical implications of oxidative stress & sperm DNA damage in normozoospermic infertile men. *The Indian Journal of Medical Research*, 134(3), 396–398.
61. Wang, Y., Zhao, T. T., Zhao, H. Y., & Wang, H. (2018). Melatonin protects methotrexate-induced testicular injury in rats. *European Review for Medical and Pharmacological Sciences*, 22(21), 7517–7525. https://doi.org/10.26355/eurrev_201811_16293
62. Xia, B., Wu, W., Fang, W., Wen, X., Xie, J., & Zhang, H. (2022). Heat stress-induced mucosal barrier dysfunction is potentially associated with gut microbiota dysbiosis in pigs. *Animal Nutrition*, 8(1), 289–299. <https://doi.org/10.1016/j.aninu.2021.05.012>
63. Xu, Y., Lei, H., Guan, R., Gao, Z., Li, H., Wang, L., Song, W., Gao, B., & Xin, Z. (2014). Studies on the mechanism of testicular dysfunction in the early stage of a streptozotocin induced diabetic rat model. *Biochemical and Biophysical Research Communications*, 450(1), 87–92. <https://doi.org/10.1016/j.bbrc.2014.05.067>
64. Zhang, S. X., Wang, D. L., Qi, J. J., Yang, Y. W., Sun, H., Sun, B. X., & Liang, S. (2024). Chlorogenic acid ameliorates the heat stress-induced impairment of porcine Sertoli cells by suppressing oxidative stress and apoptosis. *Theriogenology*, 214, 148–156. <https://doi.org/10.1016/j.theriogenology.2023.10.018>
65. Zhang, Y., Zhao, Q., Wu, D., & Lan, H. (2022). The effect of heat stress on the cellular behavior, intracellular signaling profile of porcine growth hormone (pGH) in swine testicular cells. *Cell Stress & Chaperones*, 27(3), 285–293. <https://doi.org/10.1007/s12192-022-01270-4>
66. Zhang, Z., Zhang, Z., Liu, S., Wei, S., Wei, L., Zhu, X., Ding, K., & Liu, Y. (2024b). Protective effect of selenomethionine on rabbit testicular injury induced by Aflatoxin B1. *The Science of the Total Environment*, 927, 171973. <https://doi.org/10.1016/j.scitotenv.2024.171973>